



Morphological and histological studies on the reproductive system of *Puntius sarana sarana* (Hamilton, 1822) (Cyprinidae)

Rather Mansoor Ahmad¹✉, Nagappa Basavaraja² and Gull Romisa³

Received: 21.01.2018

Revised: 28.03.2018

Accepted: 24.04.2018

Abstract

The objective of the present study was to describe the phases of gonadal of *P. sarana sarana* under captive conditions. The different stages of oogenesis and spermatogenetic development were examined microscopically. The study revealed five different morphological phases in testis development and six morphological phases in ovarian development. It was concluded that, eight stages for oocyte development and five stages of spermatozoa of the species under study were identified under microscopic studies.

Key words: Histological, testis, ovaries, stages.

Introduction

P. sarana sarana is a medium-sized carp and is reported to have moderate growth rate compared to the major carps. The high consumer preference, even at smaller size of 100–200 g, makes it a suitable alternate candidate species for diversifying carp culture and also for short-term culture in seasonal water bodies (Gopakumar *et al.*, 1999; Chakraborty *et al.*, 2003). It has also been proven that these species could be cultured along with carps (polyculture) which would increase the total production (Jena *et al.*, 2008). It is a tasty, the most popular and favorite table fish among barb species having high nutritional and market value in south Asian countries (Chakraborty *et al.*, 2007). *Puntius sarana* is distributed in the Gangetic river system and its eastern region of the country (Mohanta *et al.*, 2008). It was once common in ponds, rivers, streams, reservoir and lakes of India. Of late, the natural stocks of this species have dwindled to a great extent. Since this species possesses culture potential, its introduction into the carp polyculture system would not only help in diversification of culture practices, but also facilitate its conservation.

Author's Address

¹KVK Bandipora, Sher-e-Kashmir University of Agricultural Sciences Kashmir.

²Department of Aquaculture, College of Fisheries, KVAFSU, Mangalore Karnataka.

³Govt. Degree College, Baramulla

E-mail: mansooraqu@gmail.com

Material and Methods

Monthly samples of *P. sarana sarana* were collected for a period of one year from November 2010 to October 2011 from the stock maintained at the College of Fisheries Fish Farm.

The sampling was started when the fish aged four and a half month old (132 days), thereafter the sampling was carried out regularly at monthly intervals. Ten specimens were randomly sampled every month and dissected out. The sex and maturity stage were recorded based on the appearance of gonads to the naked eye and the weight of the freshly collected gonads was recorded. The gonads (ovaries and testis) were then preserved separately in 10% formalin for further investigations and histological studies. The fixed samples were then processed by dehydration in graded series of alcohol followed by clearing with different reagents in an automatic tissue processor. Histological slides were made using the standard paraffin technique. The tissue samples were collected from the mid-part of the gonad. The 5-6 µm sections were stained with haematoxylin and Eosin stains and were observed under a high power computer assisted microscope.

Results and Discussion

Under present investigation, the morphological and histological studies maturation studies of both the male and female gonads were conducted over a



period of one year. In this study it was also noted that the females attain maturity earlier than their male counterparts. The maturity stages of the gonads were classified based on the macroscopic examination (appearance to the naked eye) of the testis and ovary and the results are presented under different heads:

Maturity stages in male

Based on the principal changes in the morphology and appearance of the testes and ovaries of *P. sarana sarana*, the male and female gonads were classified into five (5) and six (6) maturity stages respectively:

Maturity stages in male	
Stage I (Immature)	Testes lobes were small, cord like and colourless. This stage occurred during November 10 to January '11 (Fig. 1a).
Stage II (Immature II)	The testis become slightly thicker and occupied less than 1/3 of the length of body cavity. This stage occurred from January to March (Fig. 1b).
Stage III (Maturing)	The testis became creamy white and translucent, slightly thickened, occupying ½ of the length of body cavity. This stage occurred from late April to May (Fig. 1c).
Stage IV (Mature)	Testes increased in size, occupying the entire body cavity. The testes were swollen, creamy white in colour. Milt ran with slight pressure on the abdomen. This stage occurred during June-August - September, indicating its readiness to spawn (Fig. 1d).
Stage V (Spent)	With the resorption of the sperms, there was a marked reduction in the size of testes. Testes were shrunken and occupied about half of the body cavity. This stage occurred in October (Fig. 1e).

Maturity stages in male	
Stage I (Immature or resting phase)	In this stage, ovaries were thin, small and stripe-like, creamy white in colour. No ova were visible with the naked eye. This Stage was mostly encountered in the month of November (Fig. 2a).
Stage II (Early maturing phase)	During this stage, the ovaries were stripe-like. The ovaries increased in size to occupy about one-third of the abdominal cavity and were usually characterized by creamy white with a slight yellow colouration and ova showed granular appearance. This stage was encountered in the months of January-March (Fig. 2 b).
Stage III (Advanced maturing phase)	During this stage, the ovaries increased in size. They presented a granular appearance, with a distinctly yellowish colour. The ovaries were enlarged in both size and weight, occupying nearly two-thirds of the entire length of the abdominal cavity. The ovaries possessed a close ramification of blood vessels. The yolk deposition could be seen. This stage was encountered in April and May (Fig. 2c).
Stage IV (Mature or pre spawning phase)	During this stage, the ovaries were almost at their largest size. The ovaries occupied the entire body cavity. The ovaries were yellowish in colour and the body of fish was distended and swollen. The eggs in this stage were considerably larger in size than those in the previous stage, and constituted the maximum part of the spawning ovary. This stage appeared during May and June (Fig. 2d).
Stage V (Spawning phase)	With a slight pressure on the abdomen of the female, the eggs oozed out. The ovaries were extended laterally in such a way that they covered the ventral and lateral sides of the viscera completely and occupied the entire body cavity. The ovaries were reddish yellow in colour with a thin and transparent wall. This stage was encountered from July to September, with a peak in July, indicating its spawning season (Fig. 2e).
Stage VI (Spent)	After spawning or resorption, the ovaries were usually shrunken and flaccid structures. They became greatly reduced in volume and occupied very little space in the body cavity. This stage was found during late September onwards. On applying pressure on the abdomen, degenerated eggs, accompanied by a lot of water extruded through the genital aperture (Fig. 2f).



Histology of Ovaries: Based on histological examination eight developmental stages were found in the females. The stages classified were as follows:

Stage I or Chromatin nucleolus stage

This oocyte stage was observed during the months of November and December '10 (Fig. 3a). The immature oocytes were seen aligned in an elongated form and all of them were more or less in the same phase of development. The oocyte at this stage possessed a spherical nucleus with one or few nucleoli in the nucleoplasm. The oocytes appeared to be enclosed in a nest like structure. This stage could be observed almost throughout the sampling period, but the highest number was observed in the months of November and December (3a).

Stage II or Early perinucleolar stage

These oocytes possess a number of small nucleoli found along the nuclear membrane (Fig. 3b). The size of the oocyte further increases. Accumulation of cytoplasm increases and a thin film of follicular layer encircles the cytoplasm (Fig. 3b).

Stage III or Late perinucleolar stage

These oocytes were mainly seen during January and February. The oocytes had more or less spherical shape containing a prominent central nucleus and a number of nucleoli on the periphery of the nucleus (3c). This stage was also found throughout the period of one year.

Stage IV or Yolk vesicle stage

This stage was observed during February and March. During this stage, the oocytes became larger and yolk vesicles began to accumulate in the cytoplasm at the periphery (Fig. 3d). The cytoplasm deposition increased and the nucleus still occupied a central position with several nucleoli found in the nucleus. In this stage, *zona radiata* or primary envelope became visible for the first time and the oocytes increased in size and are termed as previtellogenic oocyte (Pvo). The ovarian follicle gets differentiated into outer theca, middle granulosa and inner zona pellucida (Fig. 3e).

Stage V or Vitellogenic (yolk) stage

This stage was observed from March to May. During this stage, the ovary had previtellogenic and vitellogenic oocytes, with the latter showing different stages of yolk deposition (Fig. 3f). The number of yolk granules increases and become larger which could be termed as yolk globules (Fig.

3g). The thickness of the follicle increased and differentiated clearly into theca, granulosa and zona radiata. The oocyte size increased further but the size of the nucleus got reduced and is still in the center of the oocyte (Fig. 3h).

Stage VI or Ripe (mature) stage

This stage was common during the months of June-September. In this stage, there was an enlargement of both cortical alveoli (ca) and yolk granules and further increase in oocyte size (Fig. 3j). The nucleus started migrating away from the center towards the periphery of the oocyte. The follicular cells were cuboidal or low cuboidal in shape and were surrounded by a thin thecal layer (Fig. 3i).

Stage VII or Spent stage or Corpus luteum

A great part of the ovaries contained large numbers of empty nests or corpus luteus or post ovulatory follicle (Fig. 13k). During this stage, the oocytes lost their shape, collapsed and showed disintegration. Ovaries were characterized by the appearance of empty follicle and a few oogonia (Fig. 3l) representing the reserved stock for the next developmental cycle. These oocytes were mainly observed from September onwards.

Atretic oocyte

These oocytes were mostly found during the months of April - October. Some of the oocytes during their growth and maturity suffered resorption and disintegrated and become atretic (Fig. 3m).

Histology of testis

Histological examination of testis of *P. sarana sarana* revealed that the testis consisted of several seminiferous lobules (sl) separated by interstitial tissue which contained leydig cells (lc). The testis lobe is surrounded by a thin membrane known as tunica albuginea (ta) which is covered externally by mesorchium (m) or testicular wall (tw). The seminiferous lobule is filled with germinal cysts containing germinal cells at different stages of development. The following maturity stages of the male germ cells were observed:

Primary or resting spermatogonia

During this stage, the testicular lobule was more or less spherical and packed with mostly spermatogonia (spg). The testicular wall, i.e. tunica albuginea was considerably thicker (Fig. 4a).

Secondary spermatogonia

During this stage, the lobular mass mostly contained primary (pspg) and secondary



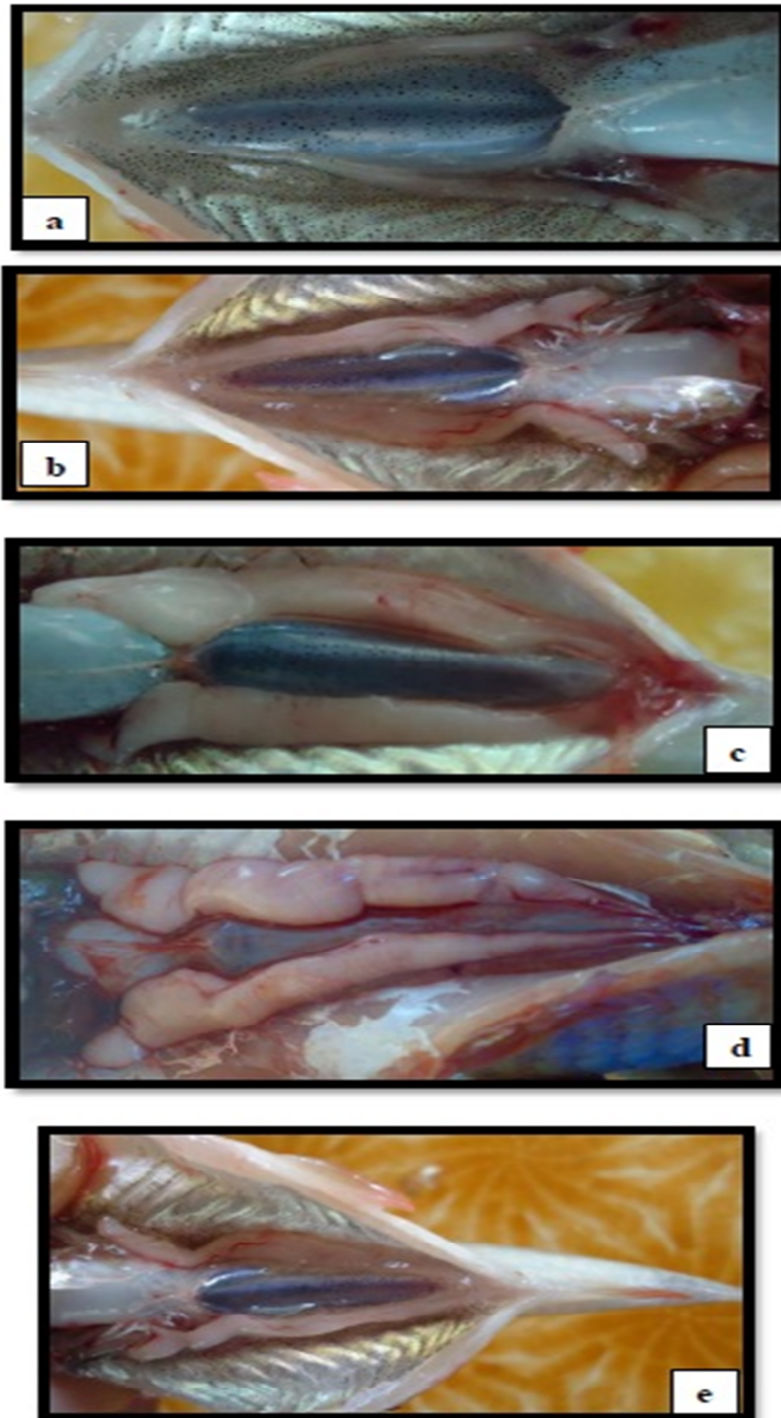


Fig.1. Maturity stages in male *P. sarana sarana*; (a) Stage I: Immature, (b) Stage II: Maturing, (c) Stage III: Mature, (d) Stage IV: Ripe and (e) Stage V: Spent.

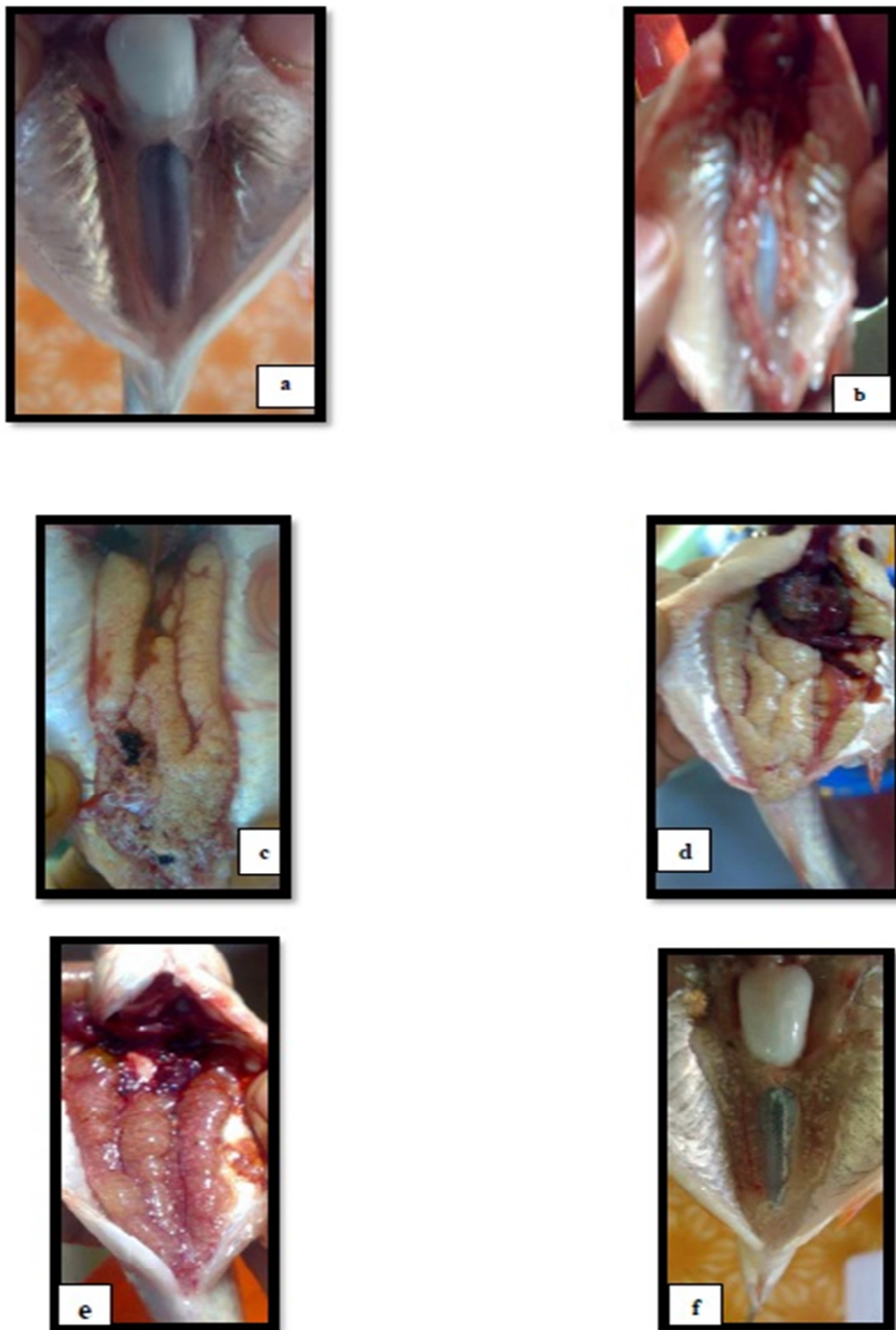


Fig. 2. Maturity stages in the female *P. sarana sarana*;
(a) Stage I (Immature or resting phase), (b) Stage II (Early maturing phase)
(c) Stage III (Advanced maturing phase), (d) Stage IV Mature or pre spawning phase. (e)
Stage V (Spawning phase) and (f) Stage VI (Spent).

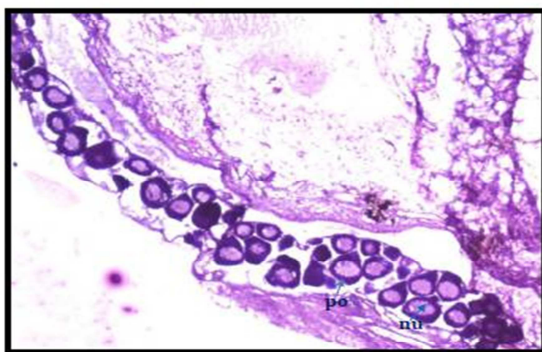


Fig.3a. Photomicrograph (4x) of immature ovary of *P.sarana sarana* showing nucleoli (nu) and perinucleolar oocytes (po).

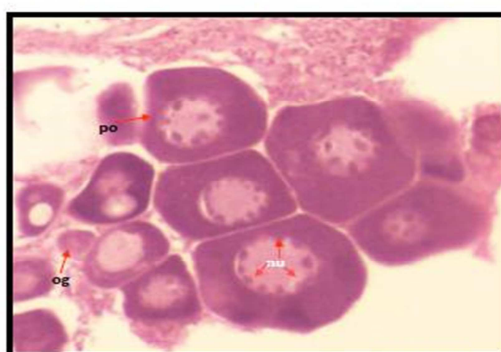


Fig. 3c: Photomicrograph of immature ovary (10x) showing oögonia (og) with nucleolus (nu) and early perinucleolar oocytes (Po).

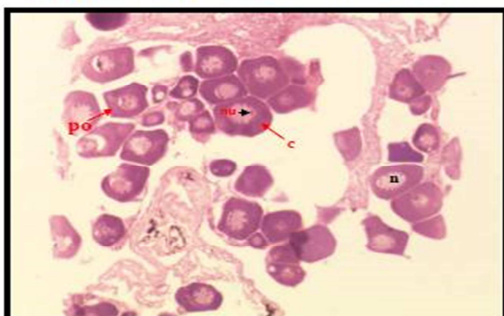


Fig. 3b. Photomicrograph of ovary (10x) showing Perinucleolar oocytes (po), nucleolus (nu), nucleus (n), and cytoplasm (c).

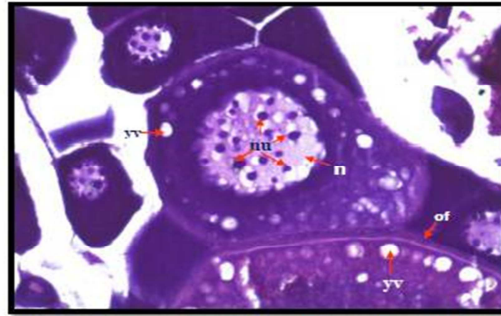


Fig.3d. Photomicrograph of ovary (40x) showing round nucleus (n) and several nucleoli (nu) in the nucleus, ovarian follicle (of) and appearance of yolk vesicles (yv).

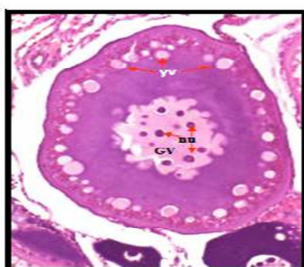


Fig. 3e: Photomicrograph of ovary (10x) showing early yolk vesicle stage with germinal vesicle (GV) and several nucleoli (Nu).

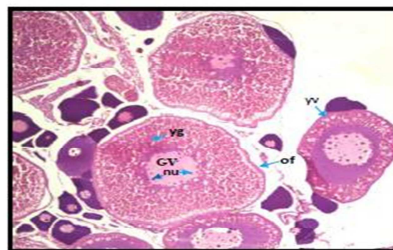


Fig. 3g: Photomicrograph of ovary (10 x) showing yolk granules (yg), yolk vesicle (yv), germinal vesicle or nucleus (Gv) and ovarian follicle (of).

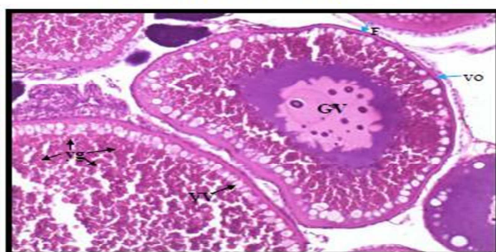


Fig.3f. Photomicrograph of ovary (40x) showing vitellogenic oocyte (vo), yolk granules (yg), follicular layer (F) and germinal vesicle (Gv).

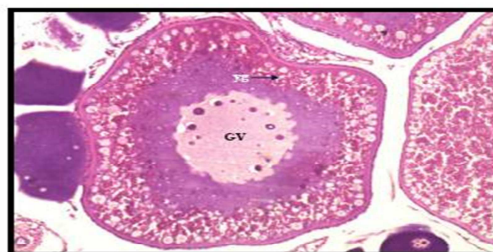

Fig. 3h: Photomicrograph of ovary (40x) showing yolk granules (yg) and germinal vesicle (Gv).

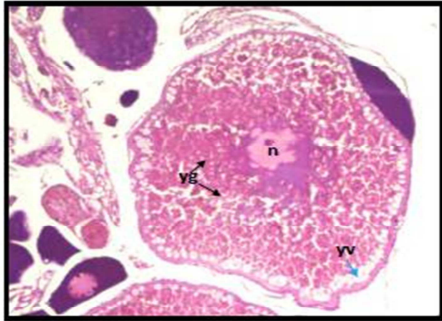


Fig. 3i: Photomicrograph of mature oocyte (10x); acentric nucleus (n), yolk vesicle (yv) and yolk granules (yg).

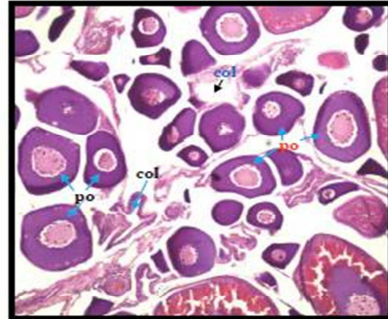


Fig. 3k: Photomicrograph (4x) showing spent ovary with perinucleolar oocytes (po) and corpus lutea (col).

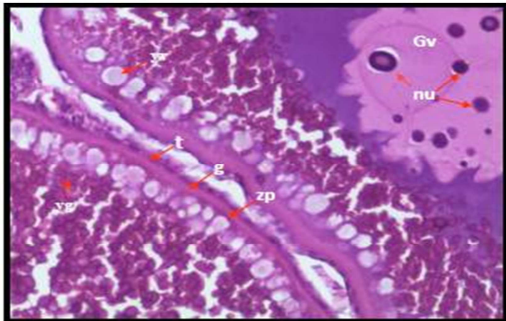


Fig.3j. Photomicrograph of follicles of two mature oocytes (40x); showing theca (t), granulosa (g), zona pellucida (zp), germinal vesicle(Gv), nucleolus (nu), yolk vesicle (yv) and yolk granules (yg).

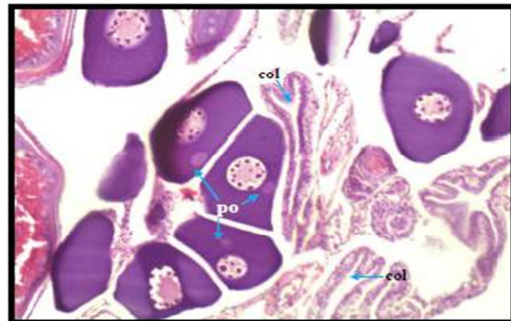


Fig. 3l: Photomicrograph (10x) showing spent ovary with perinucleolar oocytes (po) and corpus lutea (col).

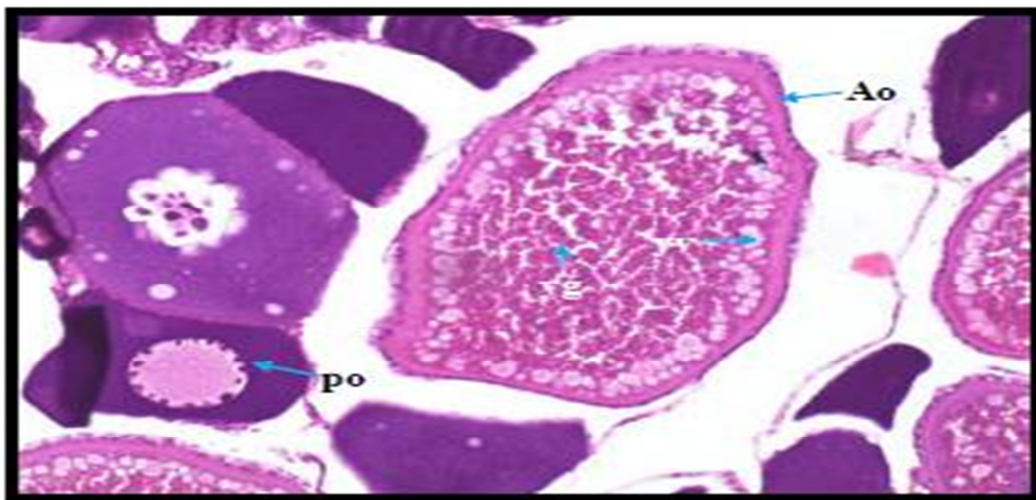


Fig.3m: Photomicrograph (20x) showing ovary with atretic oocytes(Ao), perinucleolar oocytes (po), yolk vesicle (yv) and yolk granules (yg).

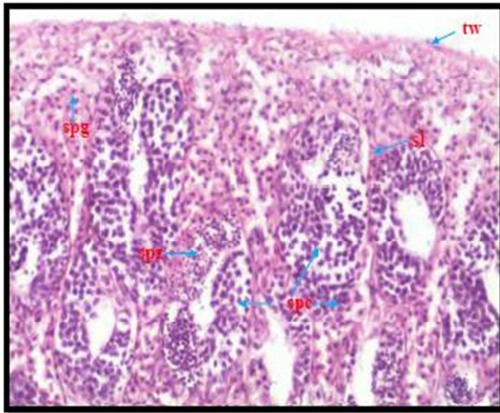


Fig. 4a. Photomicrograph of testes (10x) showing seminiferous lobules (sl) containing spermatogonia (spg) and testis wall (tw)

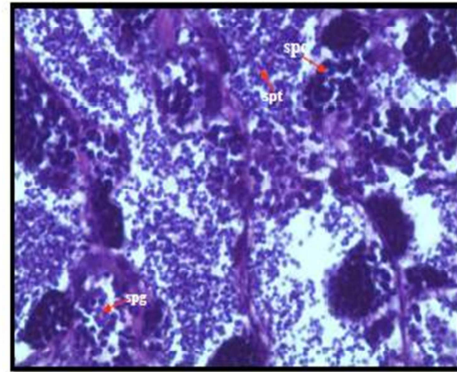


Fig. 4c: Photomicrograph of testes (40x) showing spermatocytes (spc) and spermatids (spt).

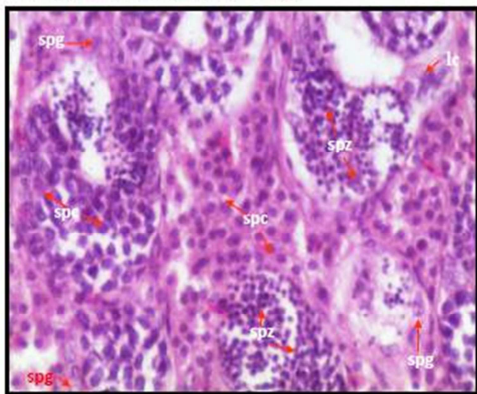


Fig. 4b. Photomicrograph of testes (20x) showing spermatogonia (spg), spermatozoa (spz), spermatocyte cysts (spc) and interstitial leydig cells (lc).

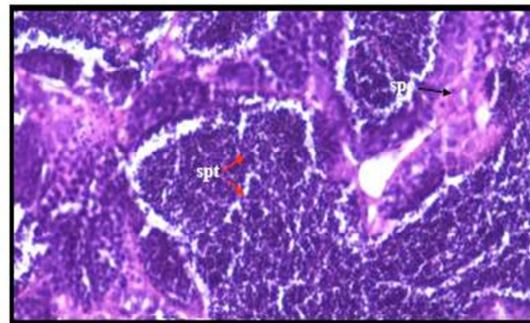


Fig. 4d: Photomicrograph of testes (20x) showing spermatocytes (spc).

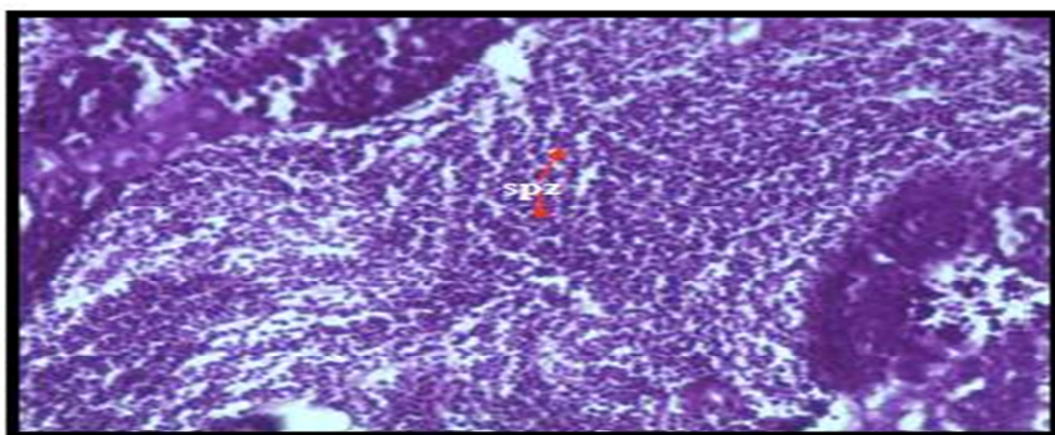


Fig.4e: Photomicrograph of mature testes (40x) showing spermatozoa (spz).

spermatogonia (sspg). The leydig cells along with the blood vessels could be seen in the interstitial mass. Most of the primary and secondary spermatogonia are packed inside the cysts (Fig. 4b).

Spermatocytes (Spc)

The lobular wall becomes thinner and the lobular volume further increases while the interlobular space is further reduced. The spermatogonia are transformed into spermatocytes (Fig. 4c). Some spermatids are also present. The lobules become packed with spermatocytes and spermatids which are found in the cysts (Fig. 4c). Primary spermatocytes were found in germinal cysts and were smaller than spermatogonia. Spermatocytes were prominent in the months of March and April.

Spermatids (Spt)

In this stage the seminiferous lobule is filled with spermatids (transformation of spermatocytes into spermatids) and hence the lobular wall is thin. The spermatids are smaller than the spermatocytes. They are rounded bodies, liberated from the cysts (Fig. 4d). These germ cells were observed during the spawning phase, *i.e.* during the months of June-October.

Spermatozoa (Spz)

During this stage, the spermatids were transformed into spermatozoa. Some spermatogonia were also found. This phase was observed during the peak spawning season, *i.e.* June-September and October. The spermatozoa were found randomly scattered in the lumen of the seminiferous lobules (Fig. 14e). They were released as mature spermatozoa into the sperm duct from the cysts (Fig. 14e). These spermatozoa had a small flagellum.

In the present study, based on the colour, shape, size and macroscopic examination of gonads, six maturity stages, *viz.* Stage I (Immature), Stage II (Maturing), Stage III (Advanced maturing phase), Stage IV (Mature), Stage V (Spawning) and Stage VI (Spent) were observed in female and five maturity stages *viz.* Stage I (Immature), Stage II (Maturing), Stage III (Mature), Stage IV (Ripe) and Stage V (Spent) were recognised in male. Chakraborty *et al.*, (2007) observed four maturity stages, *viz.* Premature stage (Stage I), Early maturing (Stage II), Mature (Stage III) and Spent (Stage IV) in *Puntius sarana* male. Chandrasoma and DeSilva (2008) described six maturity stages (Stage I to stage VI) in *P. sarana* female and five

maturity stages (stage I to Stage V) in *P. sarana* male. Siddiqi *et al.*, (1976) classified the maturity cycle of *L. bata* into five stages, *viz.* (I) immature; (II) maturing virgins or recovered spents; (III) ripening; (IV) ripe; (V) spent. Jena *et al.*, (2008) reported four distinct maturity stages, *viz.* recovering (stage I), ripening (stage II), ripe (stage III) and spent (stage IV) in both the male and female of *Cirrhina mrigala*. Qasim and Qayyum (1957) classified the degree of maturity of gonads in various species, *viz.* *Labeo rohita* (Ham), *Cirrhina mrigala* (Ham), *Labeo calbasu* (Ham), *Barbus sarana*, *Chela bacaila*, *Barbus stigma* and *Barbus (Tor) putitora* into five stages, *i.e.* Immature virgins, Maturing virgins, Ripening, Ripe and Spent. Sobhana and Nair (1974) divided the maturity cycle of *P. sarana subnasutus* females into seven stages (stage I- stage VII). Knowledge on reproduction including maturity stages, fecundity, duration of reproductive season and spawning behaviour permit quantification of the reproductive capacity of individual fish (Hunter *et al.*, 1992). The gonadal conditions reveal the reproductive potential of the individuals in a breeding population. Hence, the evaluation of the maturity condition of the gonads, *i.e.* ovary and testis deserves a greater attention (Chakraborty *et al.*, 2007). Similar findings were observed during the present study.

Observation of histological architecture of a tissue is the most accurate method to know the exact stage of maturation of ovary. In the present study, the histological examination of the ovarian tissues of *P. sarana sarana* revealed that the ovary consisted of various stages of female germ cells, *i.e.* oogonia, chromatin nucleolar oocyte and perinucleolar oocyte, yolk vesicle stage, and vitellogenic oocytes, ripe oocyte, etc. This indicates that the olive barb can easily attain maturity in captivity. Upto the month of April, the ovaries contained oocytes only in early developmental stages and were small in size, mostly consisted of oogonia, early and late perinucleolus stage and yolk vesicle stage, which showed that the female was immature. From June to August, which coincides with the breeding season of *P. sarana*, the female gonads contained exclusively vitellogenic oocytes. *P. sarana* ovary did not show all the oocytes at the same rate of development. Some of the oocytes became fully mature, while others remained in the maturing



stage. As the oocytes proceeded through maturation, the crystalline yolk underwent a morphological transformation; size increased, lost their crystalline structures and became spherical in shape. The mature (biggest oocytes) ovulated in the beginning of the spawning season (June and July) and this was evident by the presence of the maximum number of berried females.

Chakraborty *et al.*, (2007) also found similar developmental stages of oocytes in *P. sarana*; they reported different stages of the oocytes, viz. oogonia (Og), previtellogenic oocytes, early vitellogenic oocytes, advanced vitellogenic oocytes, mature oocytes and atretic oocyte (AO). Cek *et al.*, (2001) also reported the presence of chromatin nucleolar, perinucleolar oocytes, cortical vesicles, yolk granules and mature oocytes in Rosy Barb (*Puntius conchoni*).

In the present study, Five stages (Stage I to V) of testicular development were reported from the month of November '10 to October '11 based on the presence and abundance of different anatomical structures, viz. spermatogonia, spermatocytes, spermatids and spermatozoa. The different testicular stages observed in the present study were in close resemblance with the findings of Chakraborty *et al.*, (2007) who observed four stages of germ cells, i.e. spermatogonia (Primary and Secondary), spermatocytes (Primary and Secondary), spermatid and spermatozoa. McAdam *et al.*, (2008) recorded male germ cells in different stages of development, viz. spermatogonia, spermatocytes, spermatids and spermatozoa in tinfoil barb, *Puntius schwanenfeldii*. Hunter *et al.*, (2003) reported the presence of primary spermatogonium, secondary spermatogonium, primary spermatocyte, secondary spermatocyte, spermatid and spermatozoa in the testicular development of *L. rohita*.

References

- Cek, S., Bromage, N., Randall, C. and Rana, K., 2001. Oogenesis, Hepatosomatic and Gonadosomatic Indexes, and Sex Ratio in Rosy Barb (*Puntius conchoni*). *Turk. J. Fish. Aquat. Sci.*, 1: 33-41.
- Chakraborty, B. K., Miah, M. I., Mirza, M. J. A., Habib, M. A. B., 2003. Rearing and nursing of local Sarpunti, *Puntius sarana*, (Hamilton) at different stocking densities. *Pakistan. J. Biol. Sci.*, 6 (9): 797-800.
- Chakraborty, B.K., Mirza, Z.A, Miah, M.I., Habib, M.A.B. and Chakraborty, A., 2007. Reproductive Cycle of the Endangered Sarpunti, *Puntius sarana* (Hamilton, 1822) in Bangladesh. *Asian Fish. Sci.*, 20: 145-164.
- Chandrasoma, J. and Desilva, S. S., 2008. Reproductive biology of *Puntius sarana*, an indigenous species, and *Tilapia rendalli*, an exotic, in an Ancient Man- Made Lake in Sri Lanka. *Aquaculture.*, 12: 17-28.
- Gopakumar, K., Ayyappan, S., Jena, J. K., Sahoo, S. K., Sarkar, S. K., Satapathy, B. B., Nayak, P. K., 1999. *National Freshwater Aquaculture Development Plan*. Central Institute of Freshwater Aquaculture, Bhubaneswar, India, 75 pp.
- Hunter, J.R., Macewicz, N. C. H. Lo. and Kimbrell, C. A., 1992. Fecundity, spawning and maturity of female Dover sole *Microstomus pacificus*, with an evaluation of assumptions and precision. *Fish. Bull.*:101 -128.
- Jena, J. K., Das, P. C., Kar, S. and Singh, T. K., 2008. Olive barb, *Puntius sarana* (Hamilton) is a potential candidate species for introduction into the grow-out carp polyculture system. *Aquaculture.*, 280:154-157.
- McAdam, D. S. O., Liley, R. N. and Tan, E. S.P. 1999. Comparison of reproductive indicators and analysis of the reproductive seasonality of the tinfoil barb, *Puntius schwanenfeldii*, in the Perak River, Malaysia. *Environ. Biol. Fish.*, 55: 369-38.
- Mohanta, K. N., Subramanian, S., Komarpant, N and Saurabh, S., 2008. Alternate carp species for diversification in freshwater aquaculture in India. *Aqua. Asia Mag.*:11-15.
- Nguyen, T.T.T., Ingram, B., Sungan, S., Gooley, G., Sim, S.Y., Tinggi, D. and Desilva, S.S., 2005. Mitochondrial DNA diversity of broodstock of two indigenous mahaseer species, *Tor tambroides* and *Tor douronensis* (cyprinidae) cultured in Sarawak, Malaysia. *Aquaculture.*, 253(1-4): 259-269.
- Qasim S.Z. and Qayyum, A., 1957. Spawning frequencies and breeding seasons of some freshwater fishes with special reference to those occurring in the plains of northern India. *Indian J. Fish.*, 5: 24-43.
- Siddiqui, A. Q., Chatterjee, A. and Khan, A.A., 1976. Reproductive biology of the carp, *Labeo bata* (Ham.) from the river kali, India. *Aquaculture.*, 7: 181-191.
- Sobhana, B and Nair, N.B., 1974. Observation on the maturation and spawning of *Puntius sarana subnasutus* (Val). *Indian J. Fish.*, 21(2): 357-363.

